

## Wound Management - Using Stable Chlorine Dioxide Complex Antiseptic Solution

*Robert Wilkins BVSc, DVP, DACVP*

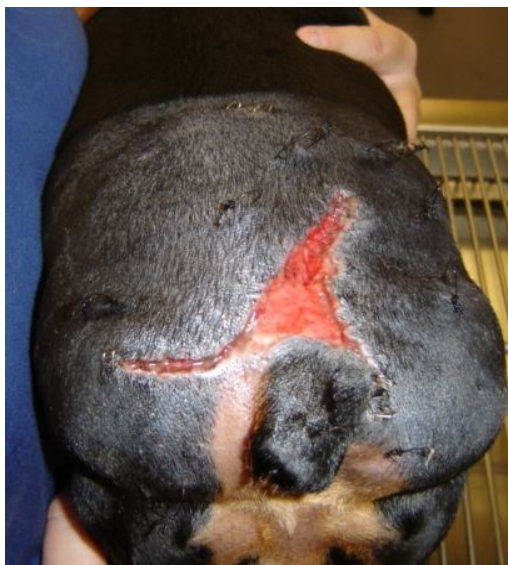With the emergence of more antibiotic resistant bacteria, increasingly virulent strains, and new pathogens, the need to find more effective, safe, wide spectrum antimicrobial agents in veterinary medicine is imperative. One such agent is chlorine dioxide. A newly developed proprietary formulation of stabilized chlorine dioxide in aqueous solution (**Ciderm®SP**) has recently been introduced for use in veterinary medicine.

This formulation has been demonstrated, in in-vitro laboratory studies, to kill bacteria in one minute, and is equally microcidal against viruses, yeast and fungi. Case studies in animals have shown that an aqueous solution of chlorine dioxide is effective in the management of wounds, both in treating and preventing infection, while preserving viable tissue without irritation.

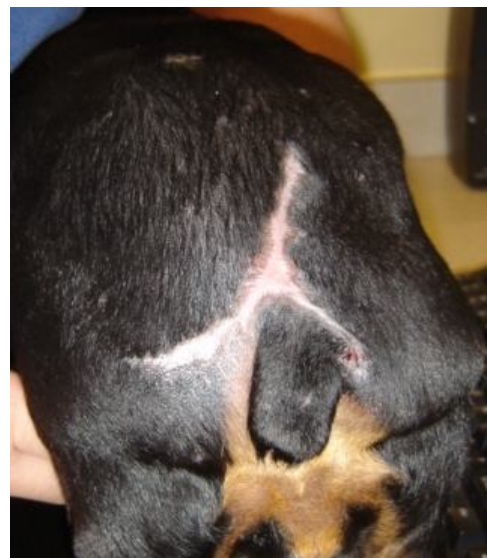### Case Study 1

*Courtesy of Dr. Alistair Chapnick, Surgeon, Veterinary Healthcare Associates, Winter Haven, Fl. 33884*

A 9 year old spayed female miniature pinscher was attacked by a large dog. The dog had a large open wound on the caudal dorsum that was treated with standard wound cleansing and closed surgically. The wound dehiscd several days later due to infection. The wound was then cleansed daily and irrigated with **Ciderm®SP** antiseptic solution and allowed to heal by secondary intention.



Open wound, secondarily infected, 3 days post injury. The lesion was irrigated and treated topically with Ciderm®SP Topical Antiseptic solution.

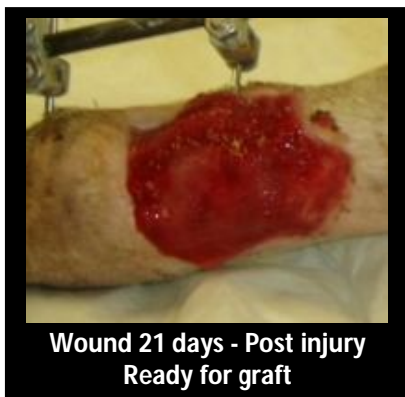

The wound healed without needing further surgical closure. This photo is 30 days post injury.

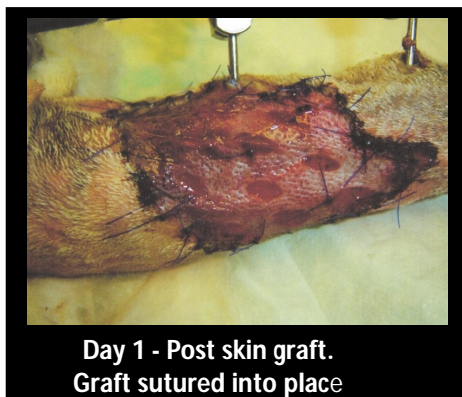## Case Study 2

Courtesy of Dr. Alistair Chapnick, Surgeon, Veterinary Healthcare Associates, Winter Haven, FL 33884

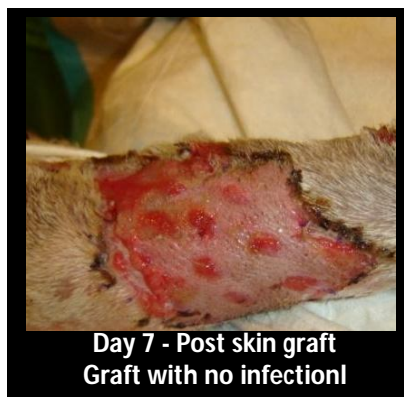An 8 year old female spayed Greyhound/Husky mix was missing for several days, returning with degloving wounds on both forelimbs. The wounds were managed by debridement and cleansing of the wounds with **Ciderm®SP** topical antiseptic solution. The injured right carpal joint was surgically stabilized with transarticular external fixation. The exposed granulated wound was grafted 21 days after the initial injury with a full thickness meshed skin graft. Wound care with **Ciderm®SP** liquid was continued as the wounds healed and contracted over a 2 month period with no secondary infection developing.



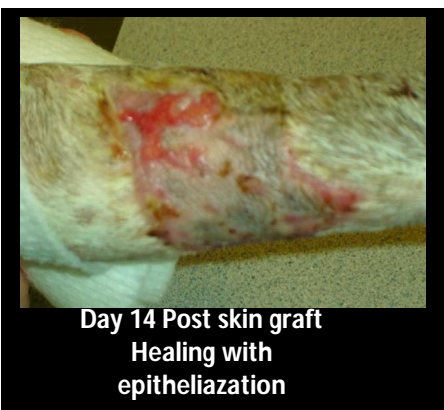Wound 21 days - Post injury  
Ready for graft



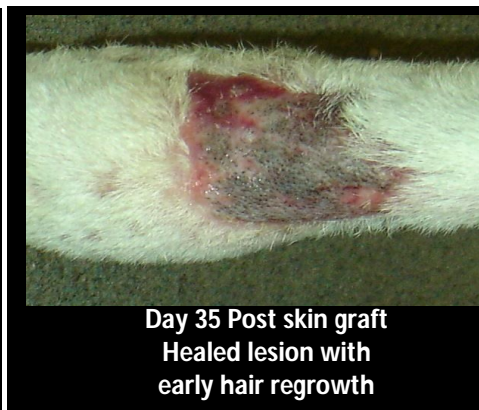Day 1 - Post skin graft.  
Graft sutured into place



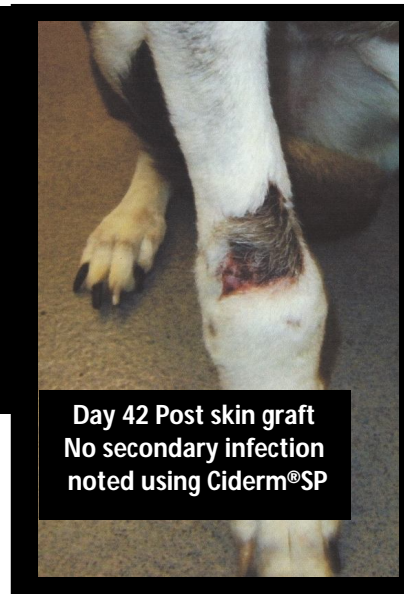
Day 7 - Post skin graft  
Graft with no infection!



Day 14 Post skin graft  
Healing with  
epithelialization



Day 35 Post skin graft  
Healed lesion with  
early hair regrowth



Day 42 Post skin graft  
No secondary infection  
noted using Ciderm®SP

The complications associated with infection in the surgical and medical wound management were eliminated by the regular use of Ciderm®SP.

## Chlorine Dioxide as an Antiseptic

Chlorine dioxide ( $\text{ClO}_2$ ) is a gas that dissolves readily in water.<sup>1,2</sup> The molecule is a free radical because of an unpaired electron which makes the compound particularly active as an oxidizing agent. Unlike chlorine ( $\text{Cl}_2$ ), chlorine dioxide is eco-friendly. It does not hydrolyze in water to form hydrochloric acid but remains in solution as a dissolved gas<sup>1</sup>. Chlorine dioxide does not form chlorinated hydrocarbons which can be carcinogenic. The aqueous solution is non-irritating to the skin.<sup>3</sup> Chlorine dioxide, as a strong oxidizing agent and a fast acting microbicidal agent, is effective at low concentrations.<sup>3</sup> It is widely used as a water purifier,<sup>1,2</sup> disinfectant and as a topical antiseptic agent with a wide spectrum of microbicidal activity against bacteria, yeast, fungi, protozoa, and viruses<sup>3</sup>. The Ciderm®SP formulation contains a stabilized Chlorine dioxide complex that retains the antiseptic properties of chlorine dioxide in a convenient aqueous solution.

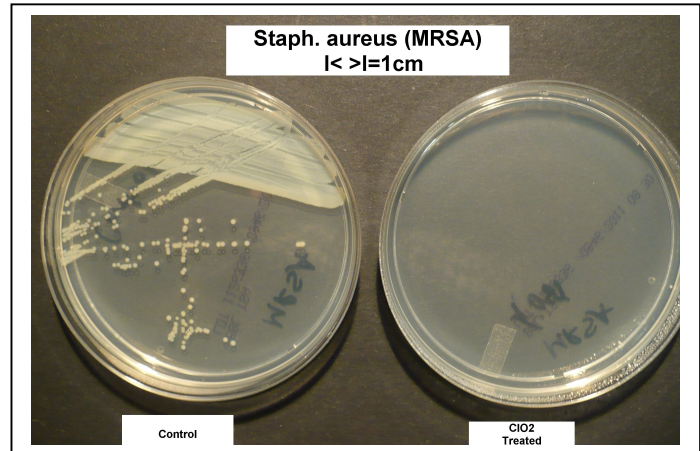


## In Vitro Study 1

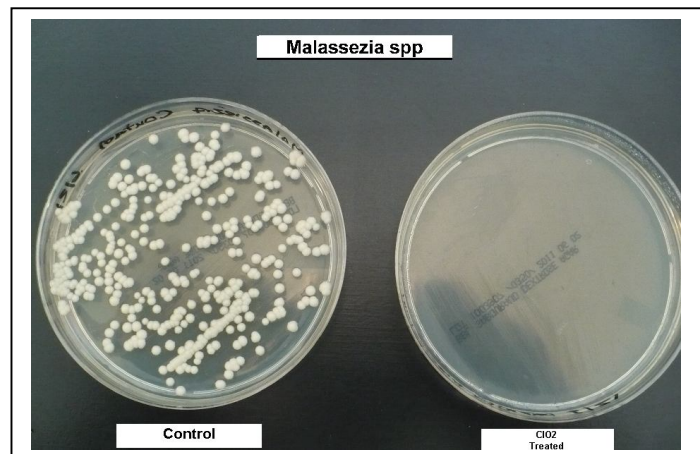
Dr. Robert J. Wilkins : Veterinary Clinical Pathologist, Englewood, FL 34223

To demonstrate the microbicidal efficacy of this stable chlorine dioxide complex solution, some common bacterial, yeast, and fungal pathogens found in small animal practice were isolated from clinical cases and exposed to Ciderm®SP spray.

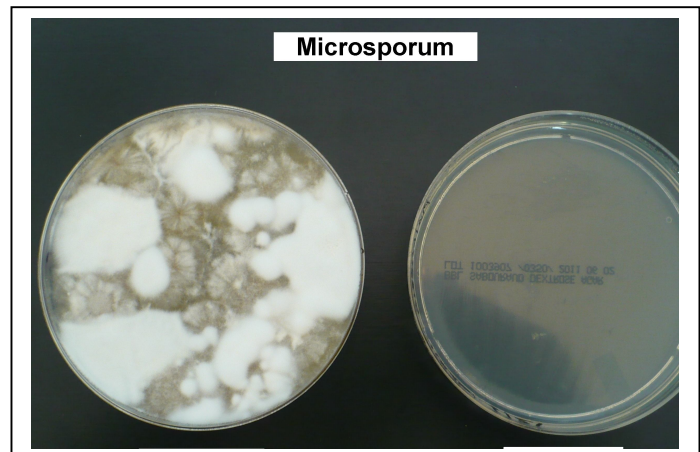
The bacteria included *Staphylococcus aureus*, *Pseudomonas aeruginosa* and *Escherichia coli*. The yeast organism was *Malassezia pachydermatis* and the fungal organism *Microsporum canis*. A standardized suspension of each bacteria was prepared and the organism was cultured onto two trypticase soy agar plates. One untreated plate was used as a control, the other was immediately sprayed with the Ciderm®SP, chlorine dioxide solution. Both plates were cultured for 18 hours after which they were inspected for growth of bacterial colonies.



The yeast and fungal organisms were isolated and each cultured directly onto two Sabouraud Dextrose Agar plates. One plate of each specimen was sprayed with the chlorine dioxide complex solution immediately and again after 24 hours. The second control plate was untreated. The plates were sealed and incubated for a total of 12 days at room temperature then inspected.



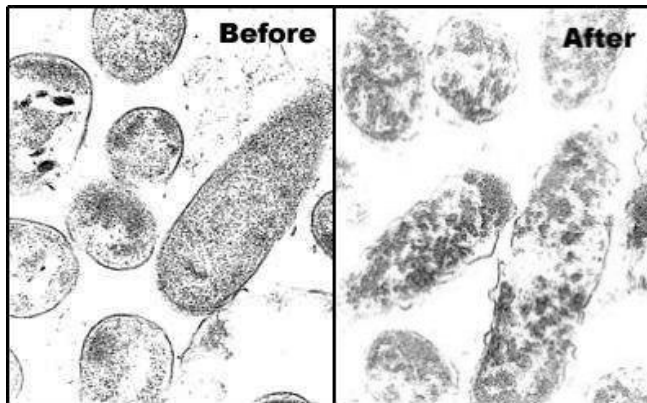
The results of this study demonstrated no bacterial growth on any of the chlorine dioxide treated plates (on the right side in each photograph taken) after the appropriate incubation period, whereas abundant growth of bacterial colonies, yeast organisms and fungal elements were noted on the respective control agar plates (shown to the left in each photograph). Identical results were obtained with the cultures of *Pseudomonas aeruginosa* and *Escherichia coli* which are not shown.



## In Vitro Study 2

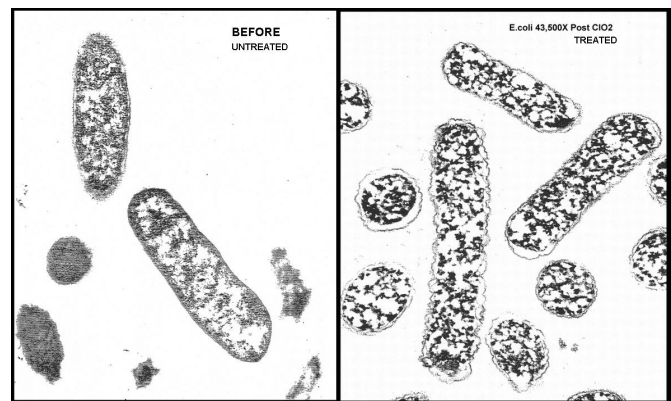
Courtesy of Howard Alliger, Frontier Pharmaceutical, Inc. Melville, NY 11747

Transmission electron micrographs taken of *Pseudomonas* and *E.coli* bacteria have demonstrated the antimicrobial effectiveness of chlorine dioxide.



(mag. 108,000 x)

*Pseudomonas aeruginosa*: before and after one minute exposure to chlorine dioxide. Note the rupture of the cell wall and the disruption of the internal organelles.



(mag. 43,000 x magnification)

*Escherichia coli*: after one minute exposure to chlorine dioxide showing similar disruption of the cell wall and clumping within the bacterial cytoplasm.

## References:

- 1) Masschelein WJ: Chlorine Dioxide. Ann Arbor Science Publishers Inc, 1979
- 2) Aieta E, Berg JD: A review of Chlorine Dioxide in Drinking Water Treatment. JAWWA 1986: 78(6): 62-76
- 3) Alliger H.: Overview of Chlorine Dioxide: Frontier Pharmaceutical Inc (2001) [www.frontierpharm.info/clo2](http://www.frontierpharm.info/clo2)

**Frontier Pharmaceutical Inc.** has developed a proprietary formulation of a stable chlorine dioxide complex in liquid form that has been incorporated into its line of veterinary antiseptic products. **Ciderm® SP** is available in dropper or spray dispensers and is used for cleaning, irrigating and direct application for the topical management of skin infections including hot spots, open wounds, ulcers, cuts, abrasions, incisions, and pododermatitis. The new formulation has eliminated mixing of two components making this single product (SP) more convenient for use in clinical practice. **Ciderm® SP** Topical Antiseptic Solution is currently available in 1oz dropper, 1oz spray, an 8oz Trigger Spray for hospital use and as a 1 oz gel.

For pricing, ordering or more information

visit [www.cidermsp.com](http://www.cidermsp.com)

email [vetproducts@frontierpharm.com](mailto:vetproducts@frontierpharm.com)

Telephone Frontier Pharmaceutical (631) 367-3400

